

Macroamylasemia in a 4-year-old girl with abdominal pain

Jeong Hee Ko, M.D. and Dae Hyoung Lee, M.D.

Department of Pediatrics, College of Medicine, Hallym University, Seoul, Korea

= Abstract =

Macroamylasemia is a benign condition characterized by abnormally large-sized serum amylase; it has been reported to occur in 1-2% of the population. In macroamylasemia, a macromolecular complex consisting of amylase linked to immunoglobulins circulates in the plasma and usually causes hyperamylasemia with low or normal amylasuria. Macroamylasemia is extremely rare in children. We report a case of a 4-year-old girl with abdominal pain and macroamylasemia, who was initially misdiagnosed as having acute pancreatitis. Failure to immediately identify macroamylase as the cause of the unexplained but benign hyperamylasemia can lead to the misdiagnosis of the condition, necessitating costly analyses for ruling out pancreatic disease and unnecessary prescriptions such as fasting and intravenous replacement therapies, as was observed in our patient. (*Korean J Pediatr* 2009;52:1283-1285)

Key Words : Macroamylasemia, Hyperamylasemia, Pancreatitis

Introduction

Macroamylasemia is a benign condition characterized by a serum amylase activity increase due to circulating macroamylase complexes whose large size prevents its urinary excretion¹⁻³. It cannot be consistently correlated with any particular disease state, and should be regarded as a benign chemical derangement. The clinical importance of macroamylasemia is the confusion of this condition with other causes of hyperamylasemia and its prevalence in the population, comprised between 1 and 2%^{3,4}. This condition should be considered in any patient with elevated levels of serum amylase activity whose serum lipase and urine amylase levels are normal because its detection can obviate a prolonged diagnostic workup. Confirmation rests on the demonstration of a macromolecular amylase component in the serum by means of chromatography, ultracentrifugation and electrophoresis⁵. In this report, we describe a 4-year-old girl with abdominal pain and macroamylasemia confused with acute pancreatitis because of high serum amylase value.

Case report

A 4-year-old girl was admitted to our hospital with 4-day history of abdominal pain and low grade fever. The abdominal pain was localized in periumbilical area of abdomen. There were no associated symptoms, such as rash, arthritis, vomiting, or diarrhea. The past medical history of her and parents was unremarkable. She had no recent travel or animal contact history. On physical examination, she appeared acutely ill. Her axillary temperature was 37.0°C, respiratory rate 20 breaths per minute, heart rate 90 beats per minute. Breath sound was clear. Her abdomen was soft without hepatomegaly. Mild tenderness on periumbilical area without rebound tenderness was noticed. The laboratory tests were as follows: peripheral white blood cell count 9,300/mm³ with 44% neutrophils and 49% lymphocytes, hemoglobin 12.3 g/dL, platelet count 320,000/mm³, ESR 23 mm/h, C-reactive protein 1.28 mg/dL (reference value <8.0 mg/dL), aspartate aminotransferase 26 IU/L, alanine aminotransferase 12 IU/L, total protein 7.2 g/dL, albumin 4.1 g/dL, total bilirubin 0.6 mg/dL, total cholesterol 179 mg/dL, alkaline phosphatase 400 IU/L, glucose 113 mg/dL, urea nitrogen 11.1 mg/dL, creatinine 0.4 mg/dL, serum amylase 687 U/L, and lipase 31 U/L. Immunoglobulin levels, anti-nuclear antibody, rheumatoid factor, and complements levels were normal.

The child was given nothing by mouth and was started on

Received : 21 July 2009, Revised : 15 September 2009

Accepted : 5 October 2009

Address for correspondence : Dae Hyoung Lee, M.D.

Department of Pediatrics, Hallym University Sacred Heart Hospital, 896, Pyeonchon-dong, Dongan-gu, Anyang-si, Gyeonggi-do, 431-070 Korea

Tele : +82.31-380-3732, Fax : +82.31-380-3733

E-mail : mdleedh@hallym.or.kr

intravenous fluid therapy. On the second hospital day, she appeared to be stable and complained only of hunger. We examined her abdomen with unremarkable findings. As serum amylase value continued to be abnormally high (>700 U/L), abdominal ultrasonography and computed tomography (CT) were performed to rule out acute pancreatitis. Results of abdominal ultrasonography and CT were normal. The amylase/creatinine clearance ratio, obtained on the fourth day of hospitalization, was 0.48% (normal 1–4%). Her serum amylase isoenzyme pattern by electrophoresis showed a broad abnormal peak toward the side of positive pole compared with regular salivary and pancreatic fractions (Fig. 1). The child was discharged after macroamylsemia was diagnosed. She was followed up for 12 months without symptom and her serum amylase level remained high.

Discussion

It has been emphasized that serum amylase elevations are not specific for pancreatic diseases and that these elevations can occur in other intra- or extraabdominal processes that need to be differentiated from pancreatic diseases⁶⁾. Extrapancreatic conditions which can cause

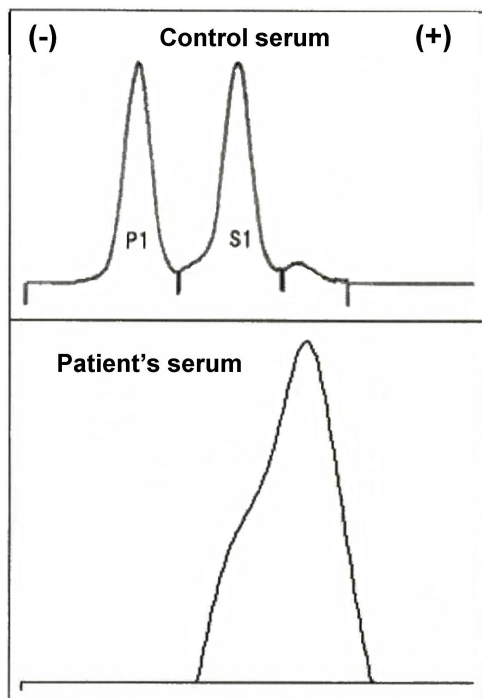


Fig. 1. Electrophoretic separation of serum amylase isoenzymes. P, pancreatic; S, salivary

hyperamylasemia are lesions of salivary glands, intestine, liver, and metabolic derangement such as diabetic ketoacidosis. Chronic elevations may occur with renal failure, liver disease, pregnancy, head injury, and rarely macroamylasemia.

In 1967, Berk et al.²⁾ reported that macroamylasemia can be the cause of the elevated serum amylase activity which was initially described by Wilding et al.¹⁾ in 1964. Wilding et al. described the presence in circulating blood of an enzymatically active macromolecular amylase complex whose large size precluded its ready excretion by kidney. The long serum half-life of macroamylase results in an elevated amylase value. An abnormally low amylase/creatinine clearance ratio [$C_{am}/C_{Cr}\% = (\text{urine amylase/serum amylase}) \times (\text{serum creatinine/urine creatinine}) \times 100$ (normal 1–4%)] reflects the retention of these large complexes by the kidney⁷⁾. In our case, amylase/creatinine clearance ratio (0.48%) was compatible with a diagnosis of macroamylasemia. Therefore, macroamylasemia should be considered in the differential diagnosis of patients who have persistently high level of serum amylase but do not exhibit any clinical symptoms of pancreatitis or salivary gland inflammation.

The pathogenesis of macroamylasemia is unclear. Complex formation with IgA type immunoglobulin was reported in 92% of the patients with macroamylasemia^{8,9)}. No IgM, IgE, or IgD macroamylases have been identified. The complex can be formed with either kappa or lambda type IgA^{8,9)}. The etiology and natural history of macroamylasemia is unclear. It has been shown to occur in patients with intestinal disease, such as celiac disease or inflammatory bowel disease^{1,5,8-10)}. It also has been reported in patients with autoimmune disease, such as systemic lupus erythematosus (SLE) and rheumatoid arthritis, and malignant disease^{5,9,11)}. Interestingly, macroamylasemia decreased or resolved after remission of the related disease^{5,10)}.

Approximately 1.5% of adults, non alcoholic hospitalized patients had macroamylasemia. The ratio of macroamylasemia in 2,900 patients with hyperamylasemia is higher¹²⁾. In pediatric population, few cases of macroamylasemia have been reported although population studies have not been carried out¹⁰⁻¹³⁾. To our knowledge, two cases of macroamylasemia were reported in Korea, one of them was a case of a 17-year-old female diagnosed with macroamylasemia and acute appendicitis and the other was

a case of 68-year-old male with alcoholic liver cirrhosis and macroamylasemia^{13, 14}.

Several methods have been proposed to determine the presence of macroamylase complexes in human serum: column chromatography, thin-layer chromatography, electrophoresis, and ultracentrifugation^{5, 6, 8, 9, 12}. As in our case, the diagnosis of macroamylasemia can be made on electrophoresis by the presence of a band that usually migrates slower or faster than normal amylase or gives diffuse pattern.

While abdominal pain is a common complaint in patients with macroamylasemia, the association itself does not establish a causal relationship between the two³. The presence of abdominal pain in patients with macroamylasemia is not surprising, as this was the primary reason for testing serum amylase level. In our patient, macroamylasemia persisted in spite of the absence of abdominal pain during follow-up.

In patients with an acute disease which may be associated with hyperamylasemia, the presence of macroamylase could make diagnosis difficult or confuse the clinician. This report emphasizes that macroamylasemia should be considered even in children when hyperamylasemia is detected in unusual clinical circumstances. The amylase/creatinine clearance ratio may be a rapid and inexpensive screening test to preclude unnecessary test and therapy.

한 글 요약

복통을 주소로 내원한 4세 여아에서 진단된 마크로아밀라제혈증 1예

한림대학교 의과대학 소아과학교실

고정희 · 이대형

마크로아밀라제혈증은 대개 혈중 아밀라아제 분자의 크기가 큰 양성 질환으로 1-2% 까지 보고된다. 마크로아밀라제혈증에서는 아밀라아제가 면역 글로불린과 결합하여 고분자 복합체를 형성하여 소변을 통한 배출이 정상 혹은 저하되어 혈청 내 고아밀라제혈증을 일으킨다. 소아에서는 매우 드문 질환이다. 본 저자들은 초기 급성 췌장염으로 오인된 4세 여아가 마크로아밀라제혈증으로 진단되어 보고하는 바이다. 고아밀라제혈증의 원인 중 하나인 마크로아밀라제혈증을 조기 진단하지 못하면 췌장 질환과 감별을 위한 고 비용의 검사를 하게 되고 금식이나 정맥 영양과 같은 필요 없는 치료를 할 수 있다.

References

- 1) Wilding P, Cooke WT, Nicholson GI. Globulin-bound amylase: a cause of persistently elevated levels in serum. *Ann Intern Med* 1964;60:1053-9.
- 2) Berk JE, Kizu H, Wilding P, Searcy RL. Macroamylasemia: a newly recognized cause for elevated serum amylase activity. *N Engl J Med* 1967;277:941-6.
- 3) Barrows D, Berk JE, Fridhandler L. Macroamylasemia: survey of prevalence in a mixed population. *N Engl J Med* 1972;286:1352.
- 4) Helfat A, Berk JE, Fridhandler L. The prevalence of macroamylasemia. Further study. *Am J Gastroenterol* 1974;62:54-8.
- 5) Van Gossum A. Macroamylasemia: a biochemical or clinical problem? *Dig Dis* 1989;7:19-27.
- 6) Kameya S, Hayakawa T, Kameya A, Watanabe T. Clinical value of routine isoamylase analysis of hyperamylasemia. *Am J Gastroenterol* 1986;81:358-64.
- 7) Levitt MD, Rapoport M, Cooperband SR. The renal clearance of amylase in renal insufficiency, acute pancreatitis, and macroamylasemia. *Ann Intern Med*. 1969;71:919-25.
- 8) Kobayashi T, Nakayama T, Kitamura M. Electrophoretic identification of serum immunoglobulins linked to amylase: macroamylase. *Clin Chim Acta* 1978;86:261-5.
- 9) Klonoff DC. Macroamylasemia and other immunoglobulin-complexed enzyme disorders. *West J Med* 1980;133:392-407.
- 10) Barera G, Bazzigaluppi E, Viscardi M, Renzetti F, Bianchi C, Chiumello G, et al. Macroamylasemia attributable to gluten-related amylase autoantibodies: a case report. *Pediatrics* 2001;107:E93.
- 11) Yoshida K, Minegishi Y, Okawa H, Yata J, Tokoi S, Kitagawa T, et al. Epstein-Barr virus-associated malignant lymphoma with macroamylasemia and monoclonal gammopathy in a patient with Wiskott-Aldrich syndrome. *Pediatr Hematol Oncol* 1997;14:85-9.
- 12) Forsman RW. Macroamylase: prevalence, distribution of age, sex, amylase activity, and electrophoretic mobility. *Clin Biochem* 1986;19:250-3.
- 13) Um JW, Kim KH, Kang MS, Choe JH, Bae JW, Hong YS, et al. Macroamylasemia in a patient with acute appendicitis: a case report. *J Korean Med Sci* 1999;14:679-81.
- 14) Lim PS, Kim SY, Yeom DH, Jo EY, Choi CS, Kim HC, et al. Macroamylasemia and macrolipasemia in patient with alcoholic liver cirrhosis. *Korean J Med* 2008;75:459-62.