

## Epidural hematoma treated by aspiration of accompanying cephalhematoma in a newborn infant

Ki Won Oh, M.D., Heng Mi Kim, M.D.

Department of Pediatrics, College of Medicine, Ulsan University Hospital, Ulsan  
Department of Pediatrics, College of Medicine, Kyungpook National University, Daegu, Korea

Epidural hematoma is relatively rare in newborn infants and frequently associated with instrumental deliveries or other complications during labor and delivery. Although surgical evacuation has been the most common therapy, many other procedures have been described. Although many epidural hematomas require surgical evacuation rather than nonsurgical management, conservative or aspiration of hematoma have been attempted. In the case of EDH associated with cephalhematoma, aspiration of cephalhematoma could be attempted because frequent features of these combination were communication between these hematoma. We report a case of successful nonsurgical management of epidural hematoma through the aspiration of accompanying cephalhematoma in a 5-day-old newborn infant. (**Korean J Pediatr 2007;50:1125-1128**)

**Key Words :** Hematoma, Epidural, Cephalhematoma, Newborn, Aspiration, Nonsurgical

### Introduction

Epidural hematoma (EDH) means hemorrhage between the cranium or cranial bone and its inner periosteum. The prevalence of EDH as a consequence of birth trauma is relatively rare<sup>1-6)</sup>. It has been suggested that the rarity of EDH in newborns is due to the specific anatomic cranial conditions in this period<sup>1-7)</sup>.

Although small EDH can be treated conservatively, larger hematoma requires evacuation of hematoma. Most cases of EDH require surgical drainage but less invasive procedures including needle aspiration of the EDH itself or communicating cephalhematoma have been described<sup>1-6, 8, 9)</sup>.

We report a case of successful nonsurgical management of EDH through the aspiration of accompanying cephalhematoma in a 5-day-old newborn infant.

### Case Report

A 5-day-old male infant was admitted to the neonatal intensive care unit due to decreased activity and swelling over

the scalp. He was born uneventfully at 40 weeks of gestation, to a 32-year-old primipara at a maternity clinic by spontaneous vaginal delivery without forceps assistance or vacuum extraction. His birth weight was 2,700 g and Apgar scores were 8 and 9 at 1 and 5 minutes, respectively. After delivery, scalp swelling was noticed but observed without evaluation and management. On the fifth day after delivery, he became lethargic and was presented to our emergency room.

On admission, his blood pressure was 84/46 mmHg, pulse rate 145/min, body temperature 36.7°C, and respiratory rate 58/min. In body measurements, body weight was 2,810 g, height 50 cm, and head circumference 34 cm. He was icteric and had about 5.4×4.3×1.5 cm sized cephalhematoma in the left parietal region. He moved his extremities well, his anterior fontanel was flat, the Moro reflex was symmetric, and his pupils were of equal size with reactive to light bilaterally. The remainder of the physical and neurological examination was unremarkable.

Laboratory analysis of the blood revealed hemoglobin 16.2 g/dL, hematocrit 48%, white blood cell count 9,120/ $\mu$ L, platelet  $160 \times 10^3/\mu$ L, ESR 2 mm/hr, CRP 0.1 mg/dL. The coagulation profiles were within normal limits and there was no RBC or WBC in CSF. Other laboratory examinations including blood chemistry and urinalysis were within normal limits except for increased serum total bilirubin level as 16.5

접수 : 2007년 8월 19일, 승인 : 2007년 9월 10일  
책임저자 : 김행미, 경북대학교 의과대학 소아과학교실  
Correspondence : Heng Mi Kim, M.D.  
Tel : 053)420-5704 Fax : 053)425-6683  
E-mail : hmkim@knu.ac.kr

mg/dL.

Plain radiograms of the skull showed a soft tissue swelling over the left parietal area. A fracture line in the underlying skull was not found in that film. On the second hospital day, a computed tomography (CT) of the head revealed an EDH in the parietal region on the left side which communicated with the cephalhematoma through a linear skull fracture. On the basis of the volume and location of the EDH and clinical manifestations of the patient, we decided to observe him closely and take a follow-up CT scan.

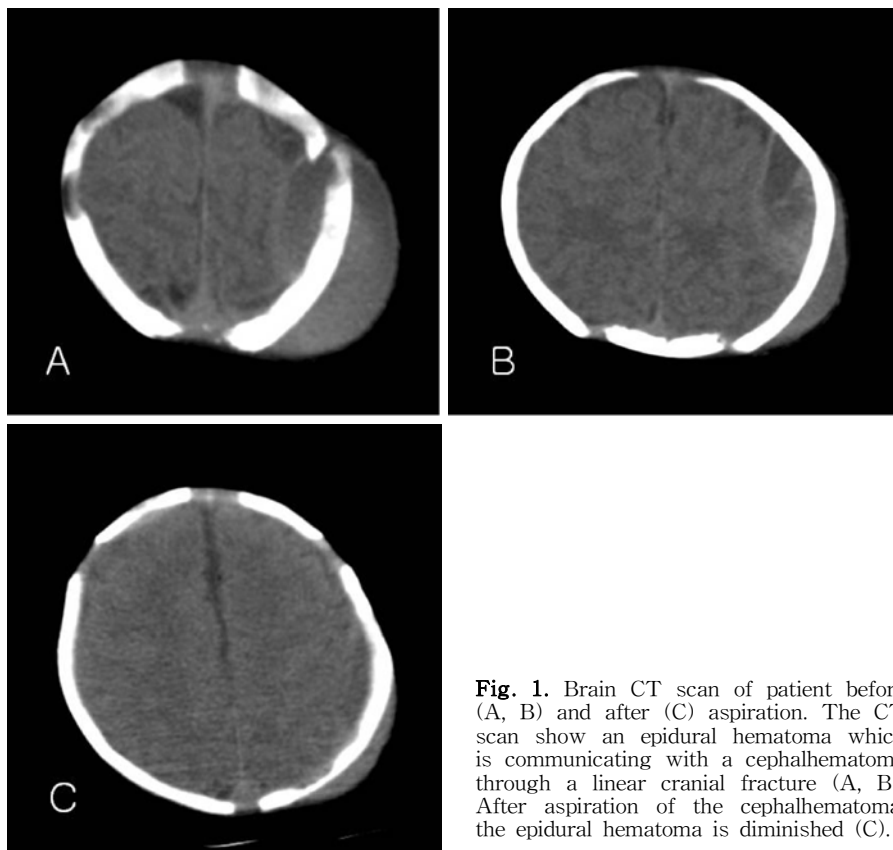
On the sixth hospital day, the 3rd CT scan revealed slight increase of the volume of the EDH, so we attempted to aspirate the cephalhematoma to evacuate the epidural blood. Aspiration of the cephalhematoma was performed with sterile technique and topical anesthesia. A 20-gauge needle attached to a 10 mL syringe was inserted perpendicular to the overlying skin of the cephalhematoma. About 27 ml dark red, unclotted blood was aspirated from the cephalhematoma, the needle was removed and a sterile pressure dressing placed. The follow-up CT scan taken immediately after aspiration showed marked decrease in the size of the EDH

and cephalhematoma.

He was discharged from the hospital 4 days after aspiration. His growth and development was followed regularly at an outpatient clinic. On a follow-up visit at 1 year, he was doing well with no neurologic deficit. He stood alone, was walking with support and picked up a small pellet with pincer grasp. He also spoke 'mama' and 'dada' and followed simple commands. Brain MRI at 12-month-old revealed no abnormal findings.

## Discussion

EDH is pathologically similar to cephalhematoma in that bleeding occurs between the cranium and its periosteum. The incidence of EDH is extremely rare in newborns accounting for only about 2% of 134 autopsies of infants that had intracranial hemorrhages<sup>10)</sup> and less than 50 cases have been reported in the literature<sup>1)</sup>. The rarity of this condition may be due to the specific anatomic cranial conditions in this period the absence of the middle meningeal artery groove, the tight attachment between the dura and periosteum and



**Fig. 1.** Brain CT scan of patient before (A, B) and after (C) aspiration. The CT scan show an epidural hematoma which is communicating with a cephalhematoma through a linear cranial fracture (A, B). After aspiration of the cephalhematoma, the epidural hematoma is diminished (C).

the poor development of the dura mater vessels<sup>1-7)</sup>.

Because EDH in neonates is only possible when the insult is enough to detach the dura mater from the cranium<sup>11)</sup>, it is frequently related with birth trauma result from instrumental deliveries or other complications during labor and delivery. Heyman et al.<sup>3)</sup> reported instrumentation was used in 9 out of the 15 infants with EDH and other review articles<sup>4,6)</sup> also described over half of the neonates with EDH were delivered with forceps or with vacuum extraction.

Although EDH primarily arises from the middle meningeal artery in older children and adults, many authors have described EDH in newborns is derived from venous rather than arterial origin<sup>4,5)</sup>. In our case, the subacute clinical feature and mild symptoms suggested an EDH of venous origin.

The latency from birth to the onset of clinical symptoms is variable. It seems to depend on the origin of bleeding, the volume of the hematoma, and the accompanied lesions. The clinical symptoms are also diverse from no specific symptoms of acute neonatal distress to neurological symptoms such as seizure and signs due to increased intracranial pressure. Heyman et al.<sup>3)</sup> reported in their clinical study seizures and hypotonia were the predominant symptoms. Sometimes the symptoms of EDH are vague, so the practitioner's intuition is important to detect the lesion.

CT or MRI scans can demonstrate the EDH effectively as convex, lentiform collection. A plain skull radiogram and ultrasonography (USG) are not sufficient to detect EDH<sup>3)</sup>, although they reveal skull fracture and other associated brain lesions. Based on review of several reports<sup>3,4,6,8)</sup>, skull fractures were found with EDH in 50-67% of cases, and USG detected only one case in six examinations<sup>3)</sup>.

The treatment modalities in newborn with EDH should be individualized based on the clinical status of the newborn, the quantity and quality of EDH revealed by CT or MRI scans, and other associated lesions<sup>3-7)</sup>.

Craniotomy with evacuation of the blood has been the prevalent approach of EDH, but nonsurgical management has been attempted also<sup>2,5-7,10)</sup>. Many authors observed relatively small EDH often needed no invasive procedures and can be resolved spontaneously<sup>4-6,12-14)</sup>. Conservative treatment can be chosen in these patients. Recently several authors<sup>15-18)</sup> attempted to define criteria for conservative treatment. Absence of focal neurological deficits, isolated hematoma less than 1 cm thick and less than 4 cm long in the antero-posterior plan with no clinical deterioration had advocated. But the hematoma is larger and expanding or associated

with a depressed cranial fracture, surgical management to drainage of hematoma is indicated<sup>3,15)</sup>.

There is reports regarding nonsurgical techniques to drain the EDH. Vachharajani and Mathur<sup>9)</sup> reported a case of ultrasound-guided needle aspiration of a EDH. Yamamoto et al.<sup>4)</sup> Negishi et al.<sup>5)</sup> and Aoki<sup>19)</sup> reported 5 cases of neonates with EDH which could be successfully evacuated by aspiration of coexistent cephalhematoma. Like our case, the common feature of above 5 cases was a communication between the cephalhematoma and the EDH through the skull fracture. All of these EDH including our case was evacuated successfully through a single aspiration of the accompanying cephalhematoma.

The review articles<sup>3,4,6)</sup> describe that 61-70% of EDH is coexisted with cephalhematoma and half of these cases had communication between EDH and cephalhematoma<sup>4)</sup>. Therefore in the neonate with EDH accompanying cephalhematoma, aspiration of the cephalhematoma can be attempted before surgical management because it may be effective and less invasive technique to drain the EDH.

**한글 요약**

**신생아에서 동반된 두혈종 흡인으로 치료된 경막외출혈 1례**

울산대학교 의과대학 소아과학교실  
경북대학교 의과대학 소아과학교실\*

오기원 · 김행미\*

신생아기에 발생하는 경막외출혈은 매우 드문 분만손상 중 하나로 주로 기구분만이나 분만과 관련된 합병증과 연관이 많은 편이다. 치료로는 수술적 배혈이 주로 시도되고 있으나 수술적 치료 이외의 고식적 치료, 경막외 혈종의 흡인, 동반된 두혈종을 통한 흡인 등 다양한 비수술적 방법들이 시도되고 있다. 저자들은 두혈종이 동반된 경막외출혈을 보였던 5일된 신생아에 대해 동반된 두혈종 흡인을 통해 경막외출혈을 비수술적으로 치료하였기에 문헌 고찰과 함께 보고하는 바이다.

**References**

- 1) Noetzel MJ. Perinatal trauma and cerebral palsy. Clin Perinatol 2006;33:355-66.
- 2) Uhing MR. Management of birth injuries. Clin Perinatol 2005;32:19-38.
- 3) Heyman R, Heckly A, Magagi J, Pladys P, Hamlat A. Intracranial epidural hematoma in newborn infants: clinical study of 15 cases. Neurosurgery 2005;57:924-9.

- 4) Yamamoto T, Enomoto T, Nose T. Epidural hematoma associated with cephalohematoma in a neonate—case report. *Neurol Med Chir (Tokyo)* 1995;35:749–52.
- 5) Negishi H, Lee Y, Itoh K, Suzuki J, Nishino M, Takada S, et al. Nonsurgical management of epidural hematoma in neonates. *Pediatr Neurol* 1989;5:253–6.
- 6) Akiyama Y, Moritake K, Maruyama N, Takamura M, Yamasaki T. Acute epidural hematoma related to cesarean section in a neonate with Chiari II malformation. *Childs Nerv Syst* 2001;17:290–3.
- 7) Gama CH, Fenichel GM. Epidural hematoma of the newborn due to birth trauma. *Pediatr Neurol* 1985;1:52–3.
- 8) Vinchon M, Pierrat V, Tchofo PJ, Soto-Ares G, Dhellemmes P. Traumatic intracranial hemorrhage in newborns. *Childs Nerv Syst* 2005;21:1042–8.
- 9) Vachharajani A, Mathur A. Ultrasound-guided needle aspiration of cranial epidural hematoma in a neonate: treating a rare complication of vacuum extraction. *Am J Perinatol* 2002;19:401–4.
- 10) Takagi T, Nagai R, Wakabayashi S, Mizawa I, Hayashi K. Extradural hemorrhage in the newborn as a result of birth trauma. *Childs Brain* 1978;4:306–18.
- 11) Hamlat A, Heckly A, Adn M, Poulain P. Pathophysiology of intracranial epidural haematoma following birth. *Med Hypotheses* 2006;66:371–4.
- 12) Hymel KP. Traumatic intracranial injuries can be clinically silent. *J Pediatr* 2004;144:701–2.
- 13) Pozzati E, Tognetti F. Spontaneous healing of acute extradural hematomas: study of twenty-two cases. *Neurosurgery* 1986;18:696–700.
- 14) Pang D, Horton JA, Herron JM, Wilberger JE, Jr., Vries JK. Nonsurgical management of extradural hematomas in children. *J Neurosurg* 1983;59:958–71.
- 15) Beni-Adani L, Flores I, Spektor S, Umansky F, Constantini S. Epidural hematoma in infants: a different entity? *J Trauma* 1999;46:306–11.
- 16) Dos Santos AL, Plese JP, Ciquini Junior O, Shu EB, Manreza LA, Marino Junior R. Extradural hematomas in children. *Pediatr Neurosurg* 1994;21:50–4.
- 17) Chen TY, Wong CW, Chang CN, Lui TN, Cheng WC, Tsai MD, et al. The expectant treatment of “asymptomatic” supratentorial epidural hematomas. *Neurosurgery* 1993;32:176–9.
- 18) Knuckey NW, Gelbard S, Epstein MH. The management of “asymptomatic” epidural hematomas. A prospective study. *J Neurosurg* 1989;70:392–6.
- 19) Aoki N. Epidural hematoma communicating with cephalhematoma in a neonate. *Neurosurgery* 1983;13:55–7.